DIGITAL MANUFACTURING OF A METAL-CERAMIC IMPLANT-SUPPORTED PROSTHESIS

Bogdan Bulancea[1†], Raluca Baciu[1†], Alice Murariu[2†], Roxana Vasluianu*[1], Dana Budala*[1], Gabriela Geletu[2]

[1] Grigore T.Popa, University of Medicine and Pharmacy Iasi, Romania, Faculty of Dental Medicine, Department of Implantology, Removable Prostheses, Dental Technology
[2] Grigore T.Popa, University of Medicine and Pharmacy Iasi, Romania, Faculty of Dental Medicine, Department of Surgicals

*Corresponding authors: Dana Budala danab1978@yahoo.com
Roxana Vasluianu roxana.vasluianu@umfiasi.ro

[†]These authors contributed equally to this work.

ABSTRACT

Digital technology has been created to minimize therapy times for both clinicians and dental technicians, as well as to reduce the number of errors that occur with traditional methods. The purpose of this paper is to illustrate the technological processes of achieving metal-ceramic dentures in the context of full-arch rehabilitation on four implants, following the stages imposed by the digital systems in the dental technique laboratory. Digital laboratory techniques were used to aesthetically restore prosthetic restoration on implants. Among the devices used in the process of performing the works on the implant, we can mention the following: Scanner, 3D printers, laser milling and sintering devices, parallelograph, etc. Prosthodontic restorations on implants provide protection for the tissues at the level of the oral cavity. Maintaining the health of the oral cavity is a main objective of improving the quality of life. From indications point of view, depending on the clinical situation, we can say that metal-ceramic prosthesis is more indicated in extended edentations, due to resistance to fracture.

Keyword: digital systems, full-arch implants, metal-ceramic denture

Introduction

The digital technology has been designed to facilitate the therapeutical times, both for the clinician and for the dental technician, as well as to reduce the number of errors that occur through classical techniques. For dental laboratories, digital systems overcome the classical techniques, ensuring high quality dentures from a biomechanical and aesthetical point of view, as well as a decrease the time of execution (1).

Prosthodontic restorations on implants provide protection for the tissues at the level of the oral cavity (2). Maintaining the health of the oral cavity is a main objective of improving the quality of life (3,4,5). The detection of incipient lesions at the level of oral cavity or the approaching of prophylactic techniques, through classical or digital technologies, contributes to reducing the risk of complications that require the surgical techniques (6,7).

Dental implants reduce charging on other elements of the oral cavity (teeth, gums, alveolar bone) because they provide crowns, bridges or removable prostheses with an independent support. In this way,

the works that are supported on the implants will not exert additional pressure on any other element of the oral cavity.

Until the present day, in the field of dental implantology, the attention has been focused mainly to obtain an osseointegration as good as possible (8).

In the meantime, due to the good and safe results offered by the long-term osseointegration technique, the goal of obtaining an aesthetic result of the treatment that is as close as possible of the characteristics of the natural dentition.

Digital techniques ensure results that give aesthetic and functional restoration as close as possible to the real situation (9). The simulations that can be made before starting the treatment, in terms of choosing the material for prosthesis, the simulation of the dental-dental movements by the correct positioning in the centric relationship represents a great step in increasing the patient's satisfaction (10).

The aim of study

The purpose of this paper is to highlight the technological processes of fabricating a metal-ceramic implant-supported prosthesis, in the context of full-arch rehabilitation on four implants, following the stages imposed by the digital systems in the dental technique laboratory.

Case presentation

The R.B. patient to whom had inserted implants at the level of teeth #3.5, #3.2, #4.2 and #4.5, had a temporary denture made of acrylic resins and subsequently a metal-ceramic denture was made using digital techniques. The implants were from Bredent range SKY multi-unit.

After recording the impression, using the classic technique, the models were scanned later. The file was sent to the milling center to obtain the metal component. The laboratory stages are highlighted in the images start with the recording of the patient in Exocad DentalCAD software (Fig. 1).

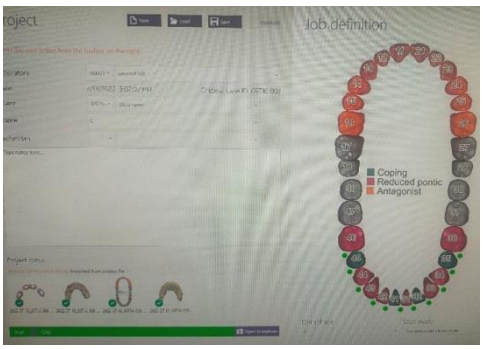

Fig.1 The patient's recording in the Exocad DentalCAD software

The software used helps us to establish the axis of insertion and disintegration of the work so that these actions may be performed easily and without tensions at the abutment level (multiunits) (fig.2-4). In the clinic step, the passivity of the metal framework was tested.

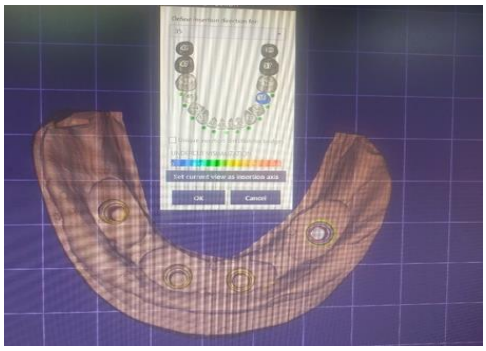

Fig. 2 The insertion axis for metal-ceramic implant-supported prosthesis was determined.



Fig. 3 The direction and the position for each implant were established

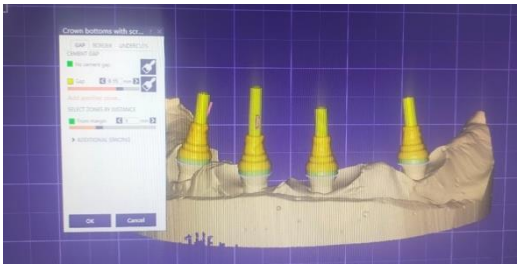

Fig. 4 The space and the areas for the luting material were created

At this stage, a simulation of the appearance and shape of the teeth was made, depending on the space available on the arch, as well as on the antagonistic arch (fig.5).

A simulation of the metallic framework was made in the form of capes without there being the welding element between the component parts of the framework, leaving the sufficient space for the ceramic component to achieve the morphology of the teeth (fig.6).

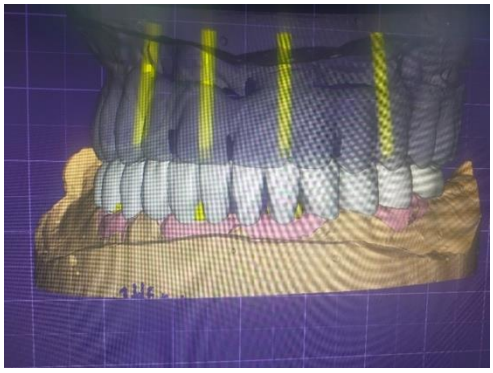

Fig. 5 Anatomical teeth arrangement

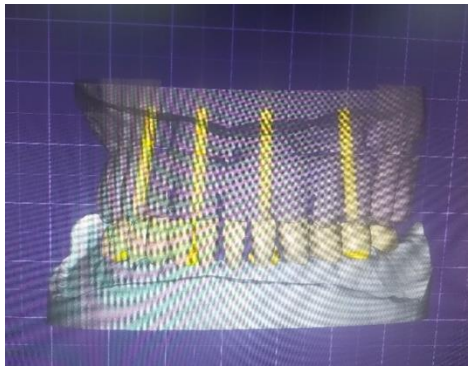

Fig. 6 Anatomical teeth reduction and modeling

After the virtual stage of the caps, the connecting elements (welding) between the components parts of the metallic framework were created, which have had various shapes, depending on the spaces available.

The metallic framework, at the mucosal level, was shaped convexly in order to avoid to retain food's debris (fig.7).

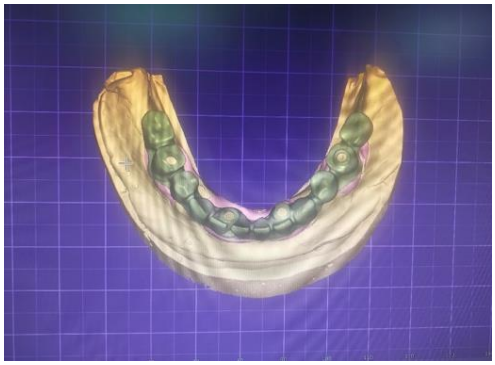

Fig.7 The metallic framework of the prothesis

In this last step, the false gum made of ceramic mass was applied, so that at the alveolar ridge and mucosal face of the denture to remain a sufficient space for cleaning and self-cleaning. After returning the prothesis to the laboratory, we proceed to the next stage of applying the glaze. In the case of smokers could be obtained shades of "smoke" at the cervical level of metalo-ceramic teeth and in the occlusal gooves (Fig.8).

Fig.8 False gum application

Discussion

One of the leading technologies in dental medicine is represented by computer- aided design and computer-aided manufacturing CAD/CAM technology. With the help of new technologies, a vertical dimension of occlusion, close to the real one, can be obtained (11).

Full-arch rehabilitation on implants can be achieved through classical prosthetic techniques and digital techniques, which improve the quality of prosthetic dentures. For digital techniques, one of the great

advantages is represented by the execution time which is lower compared to the classical technique. Among the devices used in the process of carrying out the metalo-ceramic dentures on the implant, we can mention the following: 3D scanner, 3D printers, laser milling and sintering devices, parallelographer, ceramic ovens, socket, mixer, sandblaster, various handheld devices: micromotors, turbines, etc.

The CAD/CAM system is an important tool, because it helps to guide computer devices to create objects in the virtual environment (12).

The possibility of making artifacts on the physiognomic component ensures a high-quality aesthetic restoration (1,13).

The previsualization therapy planning associated with the CAD/CAM technique, for the realization of metal-ceramic dentures, could be obtain the outstanding aesthetic results (14).

For patients with pathology present at the level of the stomatognathic system structures, it is recommended to approach a preprosthetic treatment, before starting the prosthetic treatment itself definitively (15-17).

Conclusions

1. The fabrication of metal-ceramic implant-supported prosthesis requires the use of advanced digital techniques, because the adaptation of the works, as well as their quality is superior compared to their realization by classical technique.
2. From indications point of view, depending on the clinical situation, we can say that metal-ceramic prosthesis is more indicated in extended edentations, due to resistance to fracture.
3. The use of digital techniques represents a real success in terms of meeting the criteria for performing prosthetic works on implants.

References

1. Moss, B.W.; Russell, M.D.; Jarad, F.D. The use of digital imaging for colour matching and communication in restorative dentistry. Br. Dent. J. 2005, 199, 43–49;
2. Dimofte M, Geleţu G, Costan V, Benghiac A, Moscalu M, Popescu E. Considerations of platelet rich fibrin use in oral surgery. Medical Surgical Journal. 2016; 120 (4): 920-925;
3. Murariu A, Hanganu C, Bobu L, Vasluianu R, Geleţu G, Baciu R, Stafie C, Forna NC. Comparative study of oral health systems in Europe. Romanian Journal of Oral Rehabilitation. 2020; 12 (4):11-17.
4. Murariu A, Hanganu SC. Family influences on adolescent's oral health behavior and sugar consumption. Revista de cercetare si interventie sociala. 2013; 41: 60-74.
5. Murariu, A, Hanganu, C, Vasluianu, R. Oral impact on quality of life among young adults in Iasi. Romanian Journal Of Oral Rehabilitation. 2012, 4(3): 18-22.
6. Bobu L, Murariu A, Topor G, Beznea A, Vasluianu R. Comparative evaluation of Casein Phosphopeptide – Amorphous Calcium Phosphate and Fluoride in managing early caries lesions. Revista de Chimie. 2019; 70 (10):3746-3749
7. Murariu A, Vasluianu R, Matricala L, Stoica I, Forna NC. In vitro evaluation of morphological integrity of dental enamel exposed to carbamide peroxide-based bleaching agent. Revista de Chimie. 2016; 67 (10): 2103-2105.

8. Bulancea, B, Vasluianu, R, Tatarciuc, M, ; Bulancea, A, Checherita, L, Baciu, R. Oral rehabilitation methods through the combination of different prosthetic techniques. Romanian Journal Of Oral Rehabilitatio., 2019, 11(2):266-273.
9. Ahrberg, D.; Lauer, H.C.; Ahrberg, M.; Weigl, P. Evaluation of fit and efficiency of CAD/CAM fabricated all-ceramic restorations based on direct and indirect digitalization: A double-blinded, randomized clinical trial. Clin.Oral Investig. 2016, 20, 291–300.
10. Lauritano, F.; Runci, M.; Cervino, G.; Fiorillo, L.; Bramanti, E.; Cicciù, M. Three-dimensional evaluation of different prosthesis retention systems using finite element analysis and the Von Mises stress test. Minerva Stomatologica 2016, 65, 353–367
11. Coachman C, Van Dooren E, Gürel G, Landsberg CJ, Calamita MA, Bichacho N. Smile design: From digital treatment planning to clinical reality. In: Cohen M, editor. Interdisciplinary Treatment Planning. Vol 2: Comprehensive Case Studies. Chicago: Quin- tessence; 2012: 119–74.
12. Chew AA, Esguerra RJ, Teoh KH, Wong KM, Ng SD, Tan KB. Three- Dimensional Accuracy of Digital Implant Impressions: Effects of Different Scanners and Implant Level. Int J Oral Maxillofac Implants. 2017, 32: 70–80
13. Cattoni, F.; Mastrangelo, F.; Gherlone, E.F.; Gastaldi, G. A New Total Digital Smile Planning Technique (3D-DSP) to Fabricate CAD-CAM Mockups for Esthetic Crowns and Veneers. Int. J. Dent. 2016, Special Issues.
14. Lin WS, Zandinejad A, Metz MJ, Harris BT, Morton D. Predictable restorative work flow for computer-aided design/computer-aided manufacture- fabricated ceramic veneers utilizing a virtual smile design principle. Oper Dent. 2015;40: 357–63;
15. Checherita, LE ; Lupu, IC ; Stamatin, O ; Manuc, D, Aesthetic and Functional Oral Rehabilitation with Occlussal Trays, Ultrasonotherapy and Tolperison Hydrochloride Treatment in Patients with Dysfunctional Syndrome of Stomatognathic System and Muscular Affectation, Revista de Chimie. 2018, 69(7):1752-1755.
16. Aminov, L; Sindilar, EV; Pasca, AS; Antohi, C; Decolli, Y; Stamatin, O; Costin, LI; Bulancea, BP; Francu, L; Mihalas, E; Checherita, LE ., In Vivo Evaluation of Biocompatibility of Three Biomaterials Used in Endodontics for Prosthetic Purposes in Complex Rehabilitation Treatment, Appl Sci. 2021,11(14).
17. Burlea, LS ; Stamatin, O ; Ciubara, AM; Bulancea, BP ; Lupu, IC ; Almasan, ER ; Hamburda, T ; Aminov, L ; Checherita, LE. Dental anxiety and the need for complex oral rehabilitation in patients with dysfunction syndrome of stomatognathic system and psychiatrical disease Romanian Journal Of Oral Rehabilitation, 2021,13(2); 43-51.