DETECTION OF LINGUAL FORAMINA IN THE MANDIBULAR INTERFORAMINAL REGION USING LIMITED CONE BEAM COMPUTED TOMOGRAPHY

Andrei Leonid Chirita [1], Teodora Matei [2], Mihai Predoiu [3]

[1]"Carol Davila" University of Medicine and Pharmacy – Bucharest, Romania, Faculty of Medicine, Department of Anatomy, PhD candidate
[2]"Carol Davila" University of Medicine and Pharmacy – Bucharest, Romania, Faculty of Dentistry, Student
[3]"Carol Davila" University of Medicine and Pharmacy – Bucharest, Romania, Faculty of Dentistry, Department of Anatomy, PhD candidate
Corresponding author; email: chirita.andrei45@gmail.com

ABSTRACT

Purpose: The interforaminal area, traditionally considered a relatively safe area for dental implants, is investigated in this study using limited cone beam computed tomography (CBCT) to evaluate the frequency and localization of lingual foramina that may transmit arterial branches and pose a hemorrhagic life-threatening risk.

Method: A retrospective study was conducted on 33 limited CBCT patient scans to evaluate the frequency and localization of lingual foramina. Additionally, the course and anastomosing pattern of the bony canals originating in these foramina were evaluated.

Results: All of the patients (100%) showed lingual foramina. Of the 152 lingual foramina found, 64 were median lingual foramina (MLF) and 88 were lateral lingual foramina (LLF). Continuity with the mandibular incisive canal (MIC) was seen in 31.8% (n=28) of the LLC.

Conclusion: Lingual foramina are frequently present in the anterior mandible and should be localized prior to surgical intervention in this area.

Key words: lingual foramina, lingual canals, interforaminal area, CBCT

INTRODUCTION

The interforaminal region of the mandibular body is the area located between the two mental foramina and, because this area of the mandibular body has a higher degree of cortical bone, is an elected area in dental implant placement (1). Usually, implant placement in this region is considered a routine, safe and uncomplicated procedure (2); however, complications during this procedure leading to severe hemorrhage and life-threatening upper airway obstruction have been reported by many authors (3-5). Identifying accessory foramina from the lingual surface of the mandibular body may reduce the risk of such life-threatening incidences (6).

The term "accessory foramina" was use by Sutton (7) to describe all openings in the mandibular bone other than the mandibular foramen, the mental foramen and the sockets of the teeth. More recent studies (8-14) define the foramina located on the lingual surface as lingual foramina and the bony canals originating there as lingual canals. Foramina located on the lingual surface can be divided

into median lingual foramina (MLF), located on the midline, and lateral lingual foramina (LLF), situated lateral to the mental spines. The MLF can be located above, below or between the mental spines and, according to their vertical location, can be called supraspinous, infraspinous and interspinous foramina, respectively (15).

Studies have shown that MLF are a constant finding, seen in 100% of the patients (9, 11, 12, 16). The frequency of LLF differs between studies and was reported to range from 24 to 80% of the patients (9, 10, 17) and from 30 to 50% of the sides examined (9, 16). It was also shown that the lingual canals can communicate with other anatomical structures such as mandibular canal (MC) or mandibular incisive canal (MIC) (8). Studies (18-20) have found neurovascular content in these canals that can anastomose with the inferior alveolar nerve and vessels, providing an accessory pathway for vascularization and innervation in the mandibular body and teeth.

We hypothesized that lingual foramina are well documented and that their prevalence should not show notable differences between ethnic groups. Therefore, we aimed to study the location and frequency of these foramina in a randomly selected group of Romanian patients and compare our results with those from other studies.

MATERIAL AND METHODS

We chose for this study 33 limited CBCT scans from patients that underwent radiological examination prior to mandibular implant placement. The selection criteria were based on the quality of the scans and field of view, which had to include the interforaminal area. The scans belonged to 15 men and 18 women ranging from 28 to 71 years old; the mean age was 49.9 years. All patients were fully instructed about the radiological diagnosis, and data processing was conducted in line with the Declaration of Helsinki.

For the scans, a Veraviewepocs 3D R100 (Morita, Japan) dental diagnostic machine was used with a voxel size of 0.160 mm and exposure conditions of 8 mA and 90 kV. The field of view was set to 89 x 89 mm, and the scanning time to 9.4 seconds. Using multiplanar reconstruction, the CBCT images were viewed on a computer in four different preset areas on the mandibular body: a) the median area, the area located in the midline; b) the incisive area, the area located between the midline and the lateral incisive distal surface; c) the canine area, the area located between the mesial and distal surfaces of the canine and d) the premolar area, the area located between the mesial surface of the first premolar and the distal surface of the second premolar. In these preset areas the following parameters were observed: 1) number, frequency and localization of the MLF, 2) number, frequency and localization of the LLF and 3) the course and anastomosing pattern of the lingual foramina originating from these foramina.

RESULTS AND DISCUSSIONS

Median lingual foramina

At least 1 MLF was present in 100% of the cases: the most common finding was 2 MLF, found in 57.5% of the cases, and we observed 3 MLF (Fig. 1) in 18.3% of the cases. The total number of MLF was 63, and the most common localization was supraspinous, which was seen in 93.9% of the patients. There were 26 MLF located below the mental spines seen in 25 patients, one patient having two infraspinous located foramina. Seven patients had interspinous foramen.

All of the 64 MLF had bony canals originating from the lingual foramina.

There were no anastomoses between these canals and the mandibular incisive canal. The course of the canals originating from the foramina located above the mental spines was descending in 100% of the cases. For the canals originating from the interspinous foramina, a horizontal course was detected in 85.7% of the cases and a descendant course in 14.3% of the cases. The canals located below the mental spine had an ascendant course almost all the time (96.1%) (Table I).

Lateral lingual foramina

We found a total number of 88 LLF in 31 patients (93.9% of the patients). There were 55 foramina located in the incisive area, 10 in the canine area and 23 in the premolar area. Table II describes the frequency of these foramina in the preset areas of the mandibular body on both right and left sides.

The foramina located in the incisive area were all (100%) seen between the central and lateral incisor, near the crest of the alveolar ridge, and had lingual canals originating there that descended between the two incisor roots (Fig 2). Continuity of these canals with the MIC was observed in 7.2% (4 out of 55) of the cases. In the canine area, we observed 3 (30%) foramina located near the crest of the alveolar ridge, between the canine and the lateral incisor, and 7 (70%) foramina located just below the level of the canine apex. The lingual canals originating here had a horizontal course in 70% (7) of the cases and a descending course in 30% (3). The continuity with the MIC was seen in 60% (6 out of 10) of these canals (Fig 3).

The foramina located in the premolar area were observed in 95.7% (22) of the cases, below the dental apexes and having either ascendant or horizontal lingual canals (Fig 4). One foramen (4.3%) was seen located between the first premolar and the canine, near the crest of the alveolar ridge and having a descending lingual canal (Fig 2). The continuity of these canals with the MIC could be observed in 78.2% of the cases (18 out of 23).

We found results that are similar with what others (11, 13, 14, 21) have reported regarding the frequency and localization of the MLF. Sheikhi (21) and Choi (13) found MLF present in 100% of the cases they examined and reported a frequency of 99 to 100% for the supraspinous foramen and between 70 and 74% for the infraspinous foramen. Katakami (14) found the infraspinous foramen to be less frequent, in only 57% of the study cases, but reported the presence of the interspinous in almost half of the cases (49.5%).

The number of MLF range in our study from 1 to 3, which is in accordance with most of the studies (9, 11, 16, 22, 23), even though there are authors (12, 21) who reported up to 4 foramina in this area. Sheikhi (21) and von Arx (8) found 2 MLF to be the most common finding, seen in more than 50% of the patients. Some authors (12) found the presence of only one MLF to be the most common finding, seen in 71.9% of the cases, but most of the studies (11, 13, 16, 21) reported a frequency between 20 and 30% for a single MLF. Three MLF were reported in 7.7 to 27% of cases (8, 11). Similarly, our study found one MLF in 24.2%, two MLF in 57.5% and three MLF in 18.3% of the cases.

We observed in our study that the lingual canals originating from the MLF follow a centripetal pattern in the mandibular body, with the supraspinous canals descending in 100% of the cases, the interspinous canal coursing horizontally in 85.7% of the cases and the infraspinous canals ascending in 96.1% of the cases. These lingual canals may transmit arterial branches that provide a centripetal vascular supply in the mandible, from the sublingual and submental arteries, as

proposed by Bradley (24). McDonnell (25) found the supraspinous foramen to transmit an arterial branch resulting from the anastomosis between the right and left sublingual arteries, while Liang (26) reported that the supraspinous and interspinous foramen transmit branches of the lingual artery and nerve. Another study (22) showed that the infraspinous foramina could transmit an arterial branch divided either from the sublingual artery or from the submental artery, and Madeira (20) found the mylohyoid nerve to enter the infraspinous foramen in 50% of the cases examined.

Nerve fibers can enter the mandibular body through the MLF, sensory innervating the lower incisors (7). Additional sensory innervation from the mylohyoid or lingual nerve may explain why complete anesthesia is sometimes not fully present in the lower incisors after inferior alveolar nerve block (27).

The lingual canals originating in the foramina located between the central and lateral incisor have also been called interdental canals (28), nutrient canals (29, 30) and circulatory canals (31). Hirschfeld (28) described the appearance of interdental canals and their foramina on radiographic films as radiolucent areas present between the central and lateral incisor. He stated that, occasionally, an additional canal and foramen between the lateral incisive and the canine could be seen. Kishi (29) found the incidence of nutrient canals in patients older than 61 years to be 89.7% and indicated a positive correlation between the radiographic appearance of these canals and edentulousness. Fanibunda (32) observed the foramina located between the central and lateral incisor, near the near the crest of the alveolar ridge, in 76.4% of the mandibular sides. These foramina, located between the central and lateral incisors, were named interalveolar medial foramina by Krenkel (33), who found them in 81% of the right sides and 83% of the left sides examined. In the present study, we have found LLF with descending LLCs located between the central and lateral incisors in 84.8% of the right sides and 81.8% of the left sides, which is in accordance with previous results (32, 33).

In the canine area, our results are equivalent to those reported by Katakami (14) and von Arx (8), who found the frequency of LLF in the canine area to range between 7.4 and 18.1% on the right sides and 14.9 and 20.7% on the left sides. We observed LLF in the canine area to be present in 27.2% of the patients and 15.1% of the sides. This is less than observed in a study by Choi (13), who found LLF in the canine area in 50% of the cases and in 32.5% of the sides.

Yoshida (34) evaluated the lingual foramina located in the premolar area and found them to occur in 45.7% of the evaluated sides. A study (35) that evaluated the interforaminal region found LLF in 34% of the patients. Tepper (9) observed LLF in 30.7% of the sides and in 52.9% of the patients, 15.7% of whom had bilateral LLF. A high frequency of lingual foramina in the premolar area was reported by Tagaya (10), who found them present in 80% of the patients (160 out of 200 patients), bilateral in 44% and unilateral in 36% of the cases. In this study, LLF in the premolar area were seen in 48.4% (16 out of 33) of the patients and in 34.8% (23 out of 66) of the mandibular sides, which is in accordance with other studies (8, 9, 14, 34, 35). Regarding the bilateral distribution, we observed bilateral lingual foramen in the premolar area in 21.2% (7) of the patients and unilateral foramina in 27.2% (9) of the patients.

The foramina located in the canine and premolar areas were generally (87.8%) located below the level of the dental apexes. From these foramina, horizontal or ascendant lingual canals were emerging, most of them

(82.7%) anastomosing with the MIC. Near the alveolar ridge, 4 foramina were seen, 3 between the canine and the lateral incisor and 1 between the canine and the first premolar. These foramina had descending lingual canals, none of which showed any anastomosis with the MIC, a pattern similar to what we observed in the incisive area, where 55 foramina were located near the crest of the alveolar ridge, with only 4 (7.2%) showing continuity with the MIC. It is therefore reasonable to conclude that foramina located near the crest of the alveolar ridge are transmitting lingual canals that generally show no anastomosis with the MIC and that foramina located below the level of the dental apexes transmit lingual canals that usually communicate with the MIC.

It was shown that the LLF and canals transmit communicating arterial branches derived from the submental artery (19). During implant bed preparation, the surgical drill can interrupt the course of the lingual canals containing vascular elements, which can lead to bleeding and hematoma formation in the floor of the mouth (17). This hematoma forms between the mylohyoid muscle and the sublingual mucosa, pushing the tongue upwards and backwards, which can consequently lead to upper airway obstruction (15). Because LLF and canals have been shown to be present in the interforaminal area, where they can transmit arterial anastomosis, we believe that a radiological diagnosis should precede any surgical intervention in this area.

CONCLUSIONS

1. Our results were not significantly different from the results of other authors.
2. Median lingual foramina are present in 100% of the cases, and, in most of the cases, 2 MLF can be observed in the mandibular symphysis.
3. Lateral lingual foramina located between the central and lateral incisor can be found in more than 80% of the patients.
4. The lingual foramina located in the premolar region are present in almost half of the patients, and more than 70% of the lingual canals originating here are showing continuity with the MIC.
5. Limited CBCT proved to be a suitable method for identifying lingual foramina in the interforaminal region and can help orient the clinician prior to surgical interventions in this area.

REFERENCES

1. Farré-Pagès N, Augé-Castro ML, Alaejos-Algarra F, Mareque-Bueno J, Ferrés-Padró E, Hernández-Alfaro F. Relation between bone density and primary implant stability. Med Oral Patol Oral Cir Bucal. 2011;16(1):e62-7.
2. Budihardja AS, Pytlik C, Haarmann S, Holzle F. Hemorrhage in the floor of the mouth after second-stage surgery: case report. Implant dentistry. 2006;15(2):148-52.
3. Givol N, Chaushu G, Halamish-Shani T, Taicher S. Emergency tracheostomy following life-threatening hemorrhage in the floor of the mouth during immediate implant placement in the mandibular canine region. Journal of periodontology. 2000;71(12):1893-5.
4. Mason ME, Triplett RG, Alfonso WF. Life-threatening hemorrhage from placement of a dental implant. Journal of oral and maxillofacial surgery. 1990;48(2):201-4.
5. Kalpidis CD, Konstantinidis AB. Critical hemorrhage in the floor of the mouth during implant placement in the first mandibular premolar position: a case report. Implant dentistry. 2005;14(2):117-24.

6. Kalpidis CD, Setayesh RM. Hemorrhaging associated with endosseous implant placement in the anterior mandible: a review of the literature. Journal of periodontology. 2004;75(5):631-45.
7. Sutton R. The practical significance of mandibular accessory foramina. Australian dental journal. 1974;19(3):167-73.
8. Von Arx T, Matter D, Buser D, Bornstein MM. Evaluation of location and dimensions of lingual foramina using limited cone-beam computed tomography. Journal of oral and maxillofacial surgery. 2011;69(11):2777-85.
9. Tepper G, Hofschneider UB, Gahleitner A, Ulm C. Computed tomographic diagnosis and localization of bone canals in the mandibular interforaminal region for prevention of bleeding complications during implant surgery. International Journal of Oral & Maxillofacial Implants. 2001;16(1).
10. Tagaya A, Matsuda Y, Nakajima K, Seki K, Okano T. Assessment of the blood supply to the lingual surface of the mandible for reduction of bleeding during implant surgery. Clinical oral implants research. 2009;20(4):351-5.
11. Rosano G, Taschieri S, Gaudy JF, Testori T, Del Fabbro M. Anatomic assessment of the anterior mandible and relative hemorrhage risk in implant dentistry: a cadaveric study. Clinical oral implants research. 2009;20(8):791-5.
12. Babiuc I, Ioana T, Mihaela P. Cone beam computed tomography observations of the lingual foramina and their bony canals in the median region of the mandible. Rom J Morphol Embryol. 2011;52(3):827-9.
13. Choi D-Y, Woo Y-J, Won S-Y, Kim D-H, Kim H-J, Hu K-S. Topography of the Lingual Foramen Using Micro–Computed Tomography for Improving Safety During Implant Placement of Anterior Mandibular Region. Journal of Craniofacial Surgery. 2013;24(4):1403-7.
14. Katakami K, Mishima A, Kuribayashi A, Shimoda S, Hamada Y, Kobayashi K. Anatomical characteristics of the mandibular lingual foramina observed on limited cone-beam CT images. Clinical oral implants research. 2009;20(4):386-90.
15. Von Arx T, Lozanoff S. Clinical Oral Anatomy: A Comprehensive Review for Dental Practitioners and Researchers: Springer; 2016.
16. Naitoh M, Nakahara K, Suenaga Y, Gotoh K, Kondo S, Ariji E. Comparison between cone-beam and multislice computed tomography depicting mandibular neurovascular canal structures. Oral Surg Oral Med Oral Pathol Oral Radiol Endod. 2010;109(1):e25-31.
17. Longoni S, Sartori M, Braun M, Bravetti P, Lapi A, Baldoni M, et al. Lingual vascular canals of the mandible: the risk of bleeding complications during implant procedures. Implant Dent. 2007;16(2):131-8.
18. Carter R, Keen E. The intramandibular course of the inferior alveolar nerve. Journal of anatomy. 1971;108(Pt 3):433.
19. Nakajima K, Tagaya A, Otonari-Yamamoto M, Seki K, Araki K, Sano T, et al. Composition of the blood supply in the sublingual and submandibular spaces and its relationship to the lateral lingual foramen of the mandible. Oral surgery, oral medicine, oral pathology and oral radiology. 2014;117(1):e32-e8.
20. Madeira MC, Percinoto C, das Gracas MSM. Clinical significance of supplementary innervation of the lower incisor teeth: a dissection study of the mylohyoid nerve. Oral Surg Oral Med Oral Pathol. 1978;46(5):608-14.
21. Sheikhi M, Mosavat F, Ahmadi A. Assessing the anatomical variations of lingual foramen and its bony canals with CBCT taken from 102 patients in Isfahan. Dental research journal. 2012;9(Suppl 1):S45.
22. Liang X, Jacobs R, Lambrichts I, Vandewalle G. Lingual foramina on the mandibular midline revisited: a macroanatomical study. Clinical Anatomy: The Official Journal of the American Association of Clinical Anatomists and the British Association of Clinical Anatomists. 2007;20(3):246-51.
23. Kilic E, Doganay S, Ulu M, Çelebi N, Yikilmaz A, Alkan A. Determination of lingual vascular canals in the interforaminal region before implant surgery to prevent life-threatening bleeding complications. Clinical oral implants research. 2014;25(2):e90-e3.
24. Bradley JC. Age changes in the vascular supply of the mandible. Br Dent J. 1972;132(4):142-4.

25. McDonnell D, Nouri MR, Todd M. The mandibular lingual foramen: a consistent arterial foramen in the middle of the mandible. Journal of anatomy. 1994;184(Pt 2):363.
26. Liang X, Jacobs R, Lambrichts I, Vandewalle G, van Oostveldt D, Schepers E, et al. Microanatomical and histological assessment of the content of superior genial spinal foramen and its bony canal. Dento maxillo facial radiology. 2005;34(6):362-8.
27. Stein P, Brueckner J, Milliner M. Sensory innervation of mandibular teeth by the nerve to the mylohyoid: implications in local anesthesia. Clinical Anatomy: The Official Journal of the American Association of Clinical Anatomists and the British Association of Clinical Anatomists. 2007;20(6):591-5.
28. Hirschfeld I. Interdental canals. Journal of the American Dental Association. 1927;14(4):617-31.
29. Kishi K, Nagaoka T, Gotoh T, Imai K, Fujiki Y. Radiographic study of mandibular nutrient canals. Oral Surgery, Oral Medicine, Oral Pathology. 1982;54(1):118-22.
30. Ennis LM. Roentgenographic variations of the maxillary sinus and the nutrient canals of the maxilla and the mandible. International Journal of Orthodontia and Oral Surgery. 1937;23(2):173-93.
31. Ryder Jr WB. The significance of “circulatory canals” in roentgenograms of the alveolar process. American Journal of Orthodontics and Oral Surgery. 1942;28(10):640-51.
32. Fanibunda K, Matthews J. The relationship between accessory foramina and tumour spread on the medial mandibular surface. The Journal of Anatomy. 2000;196(1):23-9.
33. Krenkel C, Holzner K, Poisel S. Hematoma of the mouth floor following oral surgery and its anatomical characteristics. Deutsche Zeitschrift fur Mund-, Kiefer-und Gesichts-Chirurgie. 1985;9(6):448.
34. Yoshida S, Kawai T, Okutsu K, Yosue T, Takamori H, Sunohara M, et al. The appearance of foramen in the internal aspect of the mental region of mandible from Japanese cadavers and dry skulls under macroscopic observation and three-dimensional CT images. Okajimas Folia Anat Jpn. 2005;82(3):83-7.
35. Trikeriotis D, Paravalou E, Diamantopoulos P, Nikolaou D. Anterior mandible canal communications: a potential portal of entry for tumour spread. Dentomaxillofacial radiology. 2008;37(3):125-9.

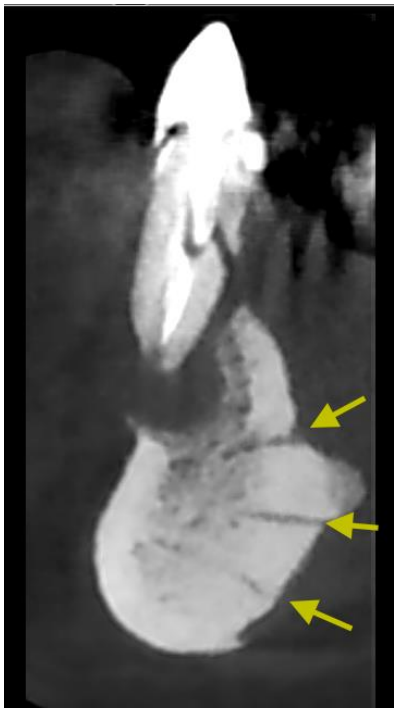

Fig 1 Sagittal section through the mandibular midline showing three median lingual canals (yellow arrows)

Note the course of the lingual canals: the supraspinous is descending, the interspinous has a horizontal course and the infraspinous is ascending.

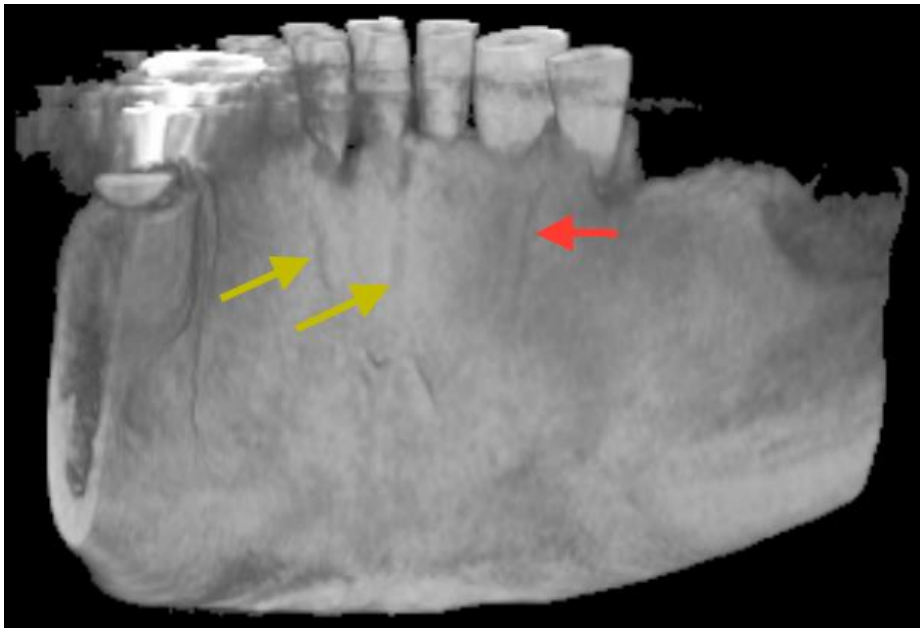

Fig 2 3D reconstruction of mandibular interforaminal area showing three lingual canals originating from foramina located near the crest of the alveolar ridge.

Yellow arrows indicating lingual canals located between the central and lateral incisors; red

arrow indicating one lingual canal located between the canine and the first premolar.

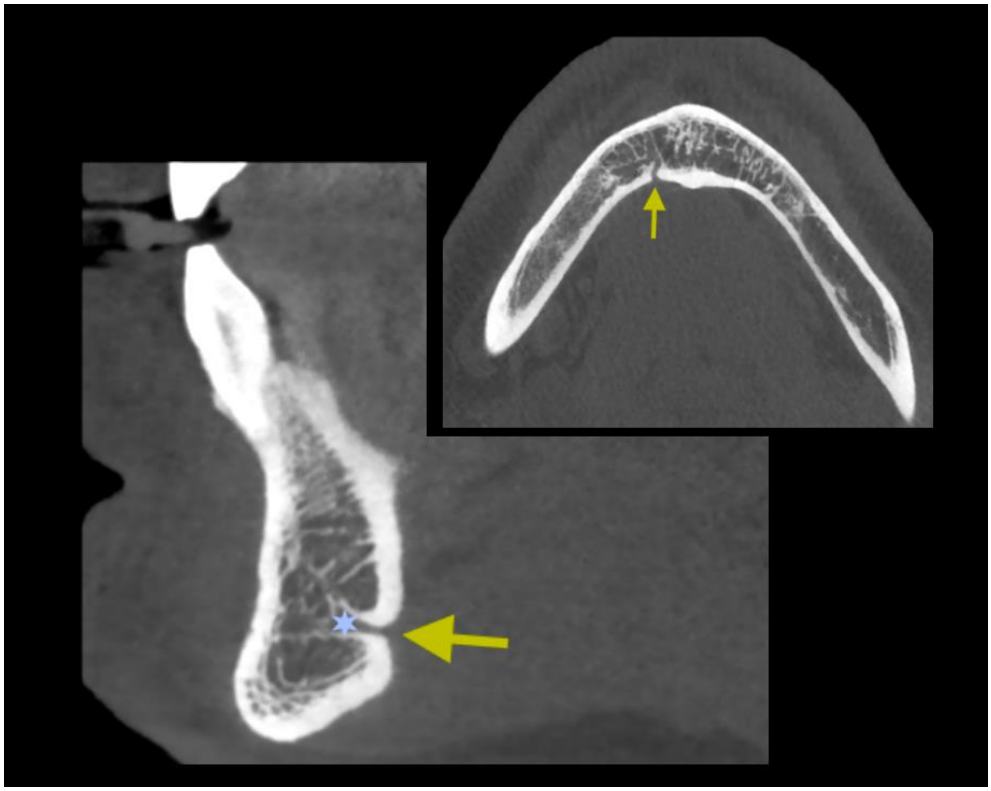

Fig 3 Sagittal section through the mandibular body showing a horizontal lingual canal (yellow arrow) below the level of the canine apex; note the communication with the mandibular incisive canal (blue star). Axial section (upper right corner) showing the same lingual canal.

Fig 4 Sagittal section through the mandibular body showing an ascendant lingual canal (yellow

arrow) in the premolar area. Note the continuity with the mandibular incisive canal.

Table I Median lingual foramina and canals.

A

	Cases	%
Supraspinous	31	93.9
Interspinous	7	21.2
Infraspinous	25	75.7

B

	Cases	%
1 Foramen	8	24.2
2 Foramina	19	57.5
3 Foramina	6	18.3

C

	Supraspinous canals	Interspinous canals	Infraspinous canals
Descendent course (%)	31 (100%)	1 (14.3%)	0
Horizontal course (%)	0	6 (85.7%)	1 (3.9%)
Ascendant course (%)	0	0	25 (96.1%)

Table II Lateral lingual foramina and canals.

A

	Cases	Frequency (%)
Right premolar area	12	36.3
Right canine area	6	18.1
Right incisive area	28	84.8
Left incisive area	27	81.8
Left canine area	4	12.1
Left premolar area	11	33.3

B

	Cases	Frequency (%)
No Foramen	2	6
1 Foramen	2	6
2 Foramina	12	36.3
3 Foramina	7	21.2
4 Foramina	9	27.2
5 Foramina	1	3

C

	Canals originating from foramina located in the premolar area	Canals originating from foramina located in the canine area	Canals originating from foramina located in the incisive area
Descending canals (%)	1 (4.3%)	3 (30%)	55 (100%)
Horizontal canals (%)	1 (4.3%)	7 (70%)	0
Ascending canals (%)	21 (91.4%)	0	0
Anastomosis with the MIC (%)	18 (78.2%)	6 (60%)	4 (7.27)