THERAPEUTIC POSSIBILITIES IN CASE OF MANDIBULAR PROGNOTHISM

Zsuzsa Oltyan [1], Klara Brânzaniuc[2], Nagy Bota Monica Cristina[2], Mariana Păcurar[1]
[1] Department of Pedodontics and Orthodontics, University of Medicine and Pharmacy, Targu Mures
[2] Department of Anatomy, University of Medicine and Pharmacy, Targu Mures,

Abstract:
Introduction: Mandibular prognothism is a serious dento-maxillary anomaly with multifactorial etiology and complex therapeutic options characterized by insufficient development of the maxilla in the sagittal direction relative to the normal development of the mandible.
Aim of study: The authors have proposed to study the possibilities of mandibular prognothism correction by maxillary expansion using two types of stress breakers, performing measurements on orthodontic pre and post-treatment samples the maxillary transverse distances (IP, IM, palate depth).
Material and method: Our study was performed in a group of 35 patients aged between 12 – 14 years old (18 young female patients and 17 young male patients) suffering from mandibular prognothism, who previously did not undergo any orthodontic treatment and durimg the treatment wore two different types of stress breakers (the first group wore Huet classical stress breaker and the other group wore Leone spider stress breakers). The jaw width index was calculated (IP, IM, and palate depth) by monitoring the degree of correction of the lateral crossbite and degree of maxillary expansion before treatment, then 6 months, 1 year and 2 years after the treatment was started,.
Results and discussions: The application of stress breaker is the technique of opening the midpalatal suture by attaining a transversal expansion. The suture undergoes the intervention in the state of fibrous joint. The patient should activate the appliance by turning the screw once a day (slow expansion). In the first three months after initiating the treatment we attained a 3 mm expansion at the premolar level and 4.5 mm at the molar level by using classical stress breaker and 3.5 respectively 4.5 mm by using spider stress breaker. Subsequent to one year treatment we could observe that the diameters were slightly increased and after two year of fixed treatment we noticed partial receding (loss of 1mm at the premolar level) in both group of patients.
Conclusions: Intermaxillary disjunction is an effective method in mandibular prognothism provided that the patient is discovered at the beginning of dentition, when sutures are active (12 -14 years in young females and 14-16 years in young males).
The two types of stress breakers work similarly, but correction is faster in case of a spider stress breaker, because of a stronger screw positioned posteriorly.

Key words: mandibular prognothism, stress breaker, maxillary expansion.

INTRODUCTION

Mandibular prognothism is an Angle class III, dento-alveolar anomaly with skeletal implications with multifactorial etiology: congenital maxillary micrognathia, pituitary dwarfism, labio-maxillo-palate cleft, post-traumatic or post-operative scars, untreated front cross-bite, aplasia of the superior lateral incisors or other hypodontias in the superior arch, bilateral extraction of the 6-year old molars and all unexpected extractions performed at the maxillary level, which

can deprive the bone of important osteogenetic centers. [1,2,3,6,7,8,16]

Rapid maxillary expansion (RME) is considered a routine technique when the separation of the midpalatal suture is achieved by strong, constant forces. This method introduced by Angle in 1860 is used for the correction of narrow maxilla, crossbite, teeth crowding and nasal obstruction. [4,13,14,17]

MATERIAL AND METHOD

The studied cases were selected patients treated at the Pediatric Dentistry Clinic, Targu Mures during 2008-2010.

Criteria for inclusion in the study were:

- age between 12-16, when the suture is active
- maxillary growth deficiency confirmed by anthropometric indexes (Zygion - Zygion) which sets the maximum width of the face.
- mandibular prognatism confirmed by values of the SNA , SNB, ANB angles
- no history of orthodontic treatment

Patients were evaluated clinically and radiologically (profile teleradiography applying the Tweed, Steiner method), and on the initial and final study models we calculated the Pont indexes, the sagittal arrow and the perimeter (Fig.1).

Fig. 1 - Measuring IP and IM on the initial model

Patients were divided into two groups, in the first group (17 patients out of which 8 young female patients and 9 young male patients) we applied the Huet stress breaker and in the second group (18 patients out of which 8 young female patients and 10 young male patients) we applied the Veltri stress breaker with spider screw (Table 1).

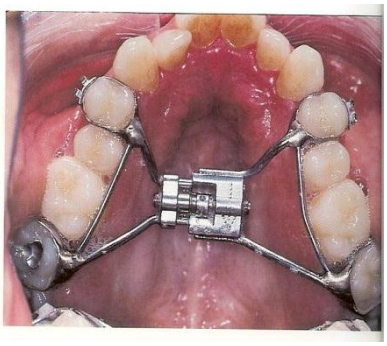

Fig. 2 Huet Stress Breaker

Fig. 3 Veltri Stress Breaker

The Huet stress breaker consists of four orthodontic rings cemented on the first premolars and primal permanent molars comprising a double Watry type screw placed between the metal bars, as high as possible on the palate. (Fig.2)

The Veltri device has a different geometry, which can be applied only on two rings and the spider-shaped screw made of stainless steel, material with good mechanical resistance and biocompatibility, which allows easy insertion in the buccal cavity and provides patients' increased comfort. (Fig.3)

Activation in both types of stress breakers is performed by the patient or a family member once a day by rotating the screw, attaining a daily expansion of 0.25 mm.

male/ female	**17**	**18**
Huet Disjunctor	9	8
Veltri Disjunctor	10	8

Tab.1 Division of patients into 2 groups

The effect of disjunction is emphasized by:

- the appearance of diastema, the disappearance of the longitudinal palatine raphe and abduction of the positions of tear ducts

Analyzing pretreatment study models in the group of patients treated with the Huet stress breaker we can assess the followings:

Pretreatment:

- transversal deficit interPM = - 7,5 mm
- transversal deficit interM = - 8,5 mm

The weighted mean value of the Pont indexes in the group of patients treated with the Veltri device is:

Pretreatment:

- transversal deficit interPM = - 7,3 mm
- transversal deficit interM = - 8,4 mm

Panoramic radiographic and teleradiographic examination (Fig. 4) confirm the diagnosis of madibular prognothism because of developmental disorders of the upper jaw. The angular and linear values are presented in Table. 2, indicating a posterior positioning of the jaw to the skull and grade III skeletal reports (ANB negative angle)[9,15,18,19].

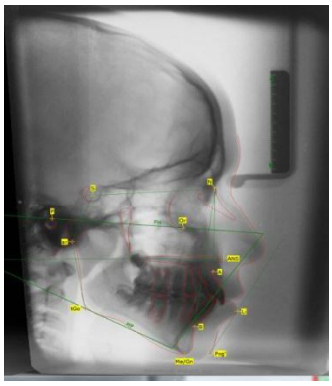

Fig. 4 Teleradiographic view

Panoramic radiographic view

Tweed Analysis	Normal	Mean Values
FMIA	67	54
FMA	25	37
IMPA	90	89
I/ i	133	127
SNA	80	78
SNB	78	79
ANB	2	-1
Wits	2mm	-4 mm
POr-OcP	10	14
Z	75	64
PFH	45 mm	40 mm
AFH	65 mm	70 mm
AFH/PFH	0,69	0,57

Tabel 2. Angular and linear values before treatment

RESULTS

3 months after the applied treatment with the Huet stress breaker we found the following values:

- transversal interPM = + 0,5 mm
- transversal interM = + 0,3 mm

Fig. 5 The aspect of plaster models before and after treatment with stress breaker

3 months after the applied treatment with the Veltri stress breaker, the values of interpremolar distances respectively intermolar distances show the same improvement (Fig. 6), however their values are slightly higher:

- transversal interPM = + 1 mm
- transversal interM = + 0,5 mm

Fig. 6 Intra-oral aspect before and after disjunction

18 months after the applied treatment a slight relapse can be detected
- transversal interPM = - 0,5 mm
- transversal interM = - 2,8 mm

We can also detect the improvement of the cephalometric indexes by correcting the SNA, ANB angles and the Wits parameter. (Table 3)

DISCUSSIONS

Relapse occurs more often because of dental than bone issues due to the repositioning tendency of the dental axes in their initial posture, hypercorrection being essential for the relative stability of the applied therapy with stress breaker[11,12.17,18,19]. The degree of hypercorrection will consider the following factors:
- inevitable partial receding
- correction of the lateral dental axes by radiculo-vestibular torque
- 2-3 mm to 4 or even 5 mm hypercorrection in Angle class III malocclusion

Tweed Analysis	Normal Values	Corrected Values
FMIA	67	54
FMA	25	37
IMPA	90	89
I/I	133	128
SNA	80	79
SNB	78	78
ANB	2	-1
Wits	2 mm	-3 mm
POr-OcP	10	14
Z	75	64
PFH	45	40
AFH	65	70
AFH/PFH	0,69	0,57

Tabel 3. Angular and linear values after treatment

The relapse rate is the highest in the first 3 years of post-treatment after which the outcome of the treatment is more stable (Magnusson A., 2009). In the 60's, Hass published good results regarding disjunction, stating that this is a reliable method for achieving a real enlargement of the base of the jaw bone.[10,11,12,13,17] McNamara's (2003) and Turpin's research (2004) confirmed the efficacy of this method. Factors that contribute to the success of this are: the type of applied stress breaker, activation technique, perimaxillary hard and soft tissue resistance and patient's age. Stress breakers can be applied in case of patients with their age ranking from 8 years (Mazoral 1990) up to 20 years (Thorne 1999)[13,14].

CONCLUSIONS

1. Maxillary disjunction contributes to the normalization of skeletal, dental relations and soft facial tissues, being an easily accepted and tolerated therapeutic procedure by patients.

2. Disjunction is an alternative treatment of Angle Class III anomalies, contributing to the growth of transversal diameter in the upper jaw (enlargement of the interpremolar and molar diameter) and at the same time correcting the position of the jaw in relation to the base of the skull.

3. Stress breakers are meant to correct morphological changes and functional disorders. Bone restructuring period and rate are approximately equal for both types of evaluated stress breakers.

REFERENCES

1. Kanno Zuisei — Early correction of a developing skeletal Class III malocclusion. The Angle Orthodontist 2007; 3: 549-556.
2. McNamara James A., Baccetti Tiziano — Gender differences in Class III malocclusion. The Angle Orthodontist 2005; 4: 510-520.
3. Battagel J. M. — The aetiological factors in Class III malocclusion. European Journal of Orthodontics 1993; 15: 347-370.
4. Bratu Elisabeta, Glăvan Florica — Ortodonţie, ortopedie dento-facială. Editura Mirton Timişoara 2005; 11: 290-296; 12: 307, 308.
5. Elham S. J., Abu Alhajia, Richardson A. — Growth prediction in Class III patients using cluster and discriminant function analysis. European Journal of Orthodontics 2003, 25:599-608.
6. Dènes József, Hidasi Gyula — Gyermekfogászat, fogszabályozás. Editura Semmelweis Budapest 1998, 18: 300-307
7. Johnston Chris, Hunt Orlaghi — The influence of mandibular prominence on facial attractiveness. European Journal of Ortodontics 2005; 27: 129-133.
8. Cocârlă Elvira — Ortodonţie, Tipografia UMF "Iuliu Haţieganu" Cluj-Napoca 1995, 93-113, 8: 136-142.
9. Cozza P., Marino A.— An orthopaedic approach to treatment of Class III malocclusions in the early mixed dentition. European Journal of Orthodontics 2004., 26: 191-199.
10. Hagg Urban, Tse Agnes — Long-term follow-up of early treatment with reverse headgear. European Journal of Ortodontics 2003; 25: 95-102.
11. Fujita T., Ayca Arman — Evaluation of maxillary protraction and fixed appliance therapy in Class III patients. European Journal of Ortodontics 2006; 28: 383-392.
12. Tse Agnes, Bendeus Margareta — A follow-up study of early treatment of pseudo Class III malocclusion. The Angle Orthodontist
13. Motoyoshi Mitsuru, Shirai Sawa — Permissible limit for mandibular expansion. European Journal of Ortodontics 2005; 27: 115-120.
14. Neslihan Tuba, Tortop Sema — A comparison of chincap and maxillary protraction appliances in the treatment of skeletal Class III malocclusions. European Journal of Ortodontics 2000; 22: 43-51.
15. Grant T., Mossey P. _— Size and shape measurment in contemporary cephalometrics. European Journal of Ortodontics 2003; 25: 231-242.
16. Perkiomani Marja R., Kyrkanidies S. — The relationship of distinct craniofacial features between Down syndrome female and their parents. European Journal of Ortodontics 2005; 27: 48-52.
17. Rey Diego, Baccetti Tiziano — Mandibular cervical headgear vs rapid maxillary expander facemask for orthopedic treatment of Class III malocclusion. The Angle Orthodontist 2007; 4: 619-624.
18. McLaughlin RP, Bennett JC, Trevisi H. - Systemized Orthodontic Treatment Mechanics, Mosby 2002:217-229
19. William R. Proffit, Henry W. Fields, David M. Sarver - Contemporary orthodontics, Mosby 2007: 395 – 430