REHABILITATION OF ALVEOLAR BONE THROUGH GUIDED TISSUE REGENERATION WITH AUTOGENOUS BONE AND XENOGRAFTS: CBCT STUDY

Tibeică(Iordan) Andreea[1],Tibeică Silviu Cătălin[2+] , Costuleanu Marcel*[2], Agop-Forna Doriana*[2], Forna Norina[1]

[1] Gr. T. Popa" U.M.Ph. - Iași, Romania, Faculty of Dentistry, Implantology, Removable Dentures, Dental Technology
[2] Gr.T.Popa" U.M.Ph. - Iași, Romania, Faculty of Dentistry, Department of Oral Surgery

Corresponding authors *: Prof. Univ. Dr. Costuleanu Marcel: e-mail mcostuleanu@yahoo.com
Prof. Univ. Dr. Agop-Forna Doriana: e-mail dr.doriana.forna@gmail.com

+ Author with the same contribution as the first author

Abstracts

The aim of the study was to assess the bone gain achieved through guided bone regeneration (GBR) techniques using bovine-origin xenograft versus porcine-origin xenograft combined with autogenous bone. Materials and method. The study was conducted on 62 patients (28 male; 34 female), aged between 40-79 years. All patients had partial edentulousness and were candidates for dental implants and the rehabilitation of the resorbed alveolar bone through guided tissue regeneration (GTR) techniques. The characteristics of the study groups are presented in Tables 1.1-1.2. Based on the type of graft material used, the patients were divided into two study groups: bovine-origin xenograft + autogenous bone group (30 patients; 41 implant sites); porcine-origin xenograft + autogenous bone group (32 patients; 50 implant sites). The CBCT examination (Sirona Orthophos XG) was used to measure alveolar bone parameters (preoperatively and six months postoperatively): height, width, and osteodensity of the alveolar bone at the implant sites. Results. The average vertical bone gain (height) was lower in alveolar sites reconstructed with bovine-origin xenografts combined with autogenous bone (5.3076 mm) compared to those reconstructed with porcine-origin xenografts combined with autogenous bone (5.8736 mm). The average horizontal bone gain (width) was higher in alveolar sites reconstructed with bovine-origin xenografts combined with autogenous bone (4.4273 mm) compared to those reconstructed with porcine-origin xenografts combined with autogenous bone (4.1624 mm). The osteodensity gain was higher in alveolar sites reconstructed with bovine-origin xenografts combined with autogenous bone (279.59 HU) compared to those reconstructed with porcine-origin xenografts combined with autogenous bone (254.24 HU). Conclusions. Post-operative bone gain in vertical and horizontal dimensions, as well as osteodensity, were statistically significant both in the overall group and for each of the investigated categories (sex, age group, location). The use of guided bone regeneration technique using combination of xenografts with autogenous bone are effective in the reconstruction of alveolar bone.

Key words: alveolar bone, guided tissue regeneration, autogenous bone, xenografts

Introduction

Autogenous bone is considered the gold standard in the field of bone regeneration biomaterials due to its regenerative properties, which include: osteoconductivity (the three-dimensional scaffold allows for the migration and proliferation of osteogenic cells), osteoinductivity (it stimulates the differentiation of mesenchymal cells into osteoblasts due to the presence of growth factors and bone morphogenetic proteins), osteogenicity (it directly contributes to the formation of new bone tissue through live osteoprogenitor cells, represented by osteoblasts and stem cells), biocompatibility (absence of risk for immunological reactions or rejection), rapid integration with the host bone, accelerating the healing process and providing superior structural stability, stimulation of bone remodeling, and adaptation to mechanical stresses, ensuring the durability of the bone augmentation area [1]. Autogenous bone block reconstruction techniques are recommended in the rehabilitation of the

DOI : 10.6261/RJOR.2024.3.16.11

posterior mandibular alveolar bone and the anterior mandibular area [2].

The regenerative properties of autogenous bone were demonstrated in a comparative study on the severely resorbed maxillary alveolar bone, where they reported no statistically significant differences in horizontal bone gain 6 months postoperatively between sites reconstructed using hBMP-2/ACS factor versus sites rehabilitated using autogenous bone blocks (3.2 ± 0.9 mm vs. 3.7 ± 1.4 mm) [3]. Some research groups have recommended the use of autogenous bone inlay blocks (harvested from the mandibular ramus) in horizontal augmentation of anterior maxillary alveolar sites [4] or mandibular sites [5].

Xenografts have many benefits: the osteoconductivity of the material promotes cell adhesion, providing optimal conditions for cell proliferation; the porous structure facilitates cell migration, nutrient exchange, and the absorption of a large volume of blood, proteins, and growth factors into the inorganic matrix; the increased surface energy facilitates osteoconduction, protein absorption, and the attachment and proliferation of osteoblasts [6]. The benefits of combining autogenous bone with various categories of bone graft materials, particularly with xenografts were demonstrated by various research groups.

Literature data demonstrated similar or significantly greater bone gain for alveolar sites reconstructed by combining autogenous bone with xenografts compared to reconstruction using xenografts as the sole graft material [7].

The benefits of combining xenografts with autogenous bone were also observed in reducing the risk of infection, postoperative complications, and increasing the structural and functional compatibility of the grafted area, as the structure and composition of autogenous bone are perfectly compatible with the host bone tissue, optimizing the functioning of the bone-implant complex post-augmentation [8]. Additionally, the association of autogenous bone with collagen membranes reduces postoperative resorption by an average of 0.9 mm and provides an additional bone gain of 0.5 mm (with no statistically significant differences compared to the control group) [9]. Considering that autogenous bone graft undergoes variable resorption during healing, which could compromise the success of the procedure, some research groups have suggested that covering the graft with a membrane can reduce graft resorption [10].

The aim of the study was to compare the bone gain achieved through guided bone regeneration (GBR) techniques using bovine-origin xenograft versus porcine-origin xenograft combined with autogenous bone.

Materials and method

Patient Selection and Study Design

The study was conducted on 62 patients (28 male; 34 female), aged between 40-79 years. All patients had partial edentulousness and were candidates for dental implants and the rehabilitation of the resorbed alveolar bone through guided tissue regeneration (GTR) techniques at the Implantology Department, Faculty of Dental Medicine, U.M.F. Grigore T. Popa Iași, for the treatment of partial mandibular edentulism.

The study group included alveolar bone areas that required the reconstruction of bone support through guided bone regeneration techniques. The study adhered to the ethical values of the Declaration of Helsinki and received approval from the ethics committee of U.M.F. "Grigore T. Popa" Iași (Romania). Each patient signed an informed consent agreement regarding the collection of data for research purposes. Inclusion Criteria: ages between 40-79 years; posterior mandibular alveolar resorption (class B-w Misch: width 2.5-4 mm, height >12 mm); absence of systemic

DOI : 10.6261/RJOR.2024.3.16.11

conditions that could affect the osseointegration of bone grafts (e.g., diabetes mellitus, disorders of phosphate-calcium metabolism, osteoporosis, treatment with bisphosphonates).Exclusion Criteria: implant sites with minimal or no alveolar resorption; presence of systemic conditions that could affect the osseointegration of bone grafts (e.g., diabetes mellitus, disorders of phosphate-calcium metabolism, osteoporosis, treatment with bisphosphonates).

The characteristics of the study groups are presented in Tables 1.1-1.2. Based on the type of graft material used, the patients were divided into two study groups:

- Bovine-origin xenograft + autogenous bone group (30 patients; 41 implant sites);
- Porcine-origin xenograft + autogenous bone group (32 patients; 50 implant sites).

Regarding the distribution of implant sites, there were no statistically significant differences in terms of age group, gender, or location.

Table 1.1. Descriptive data on subjects groups

	Total		**BioOss + autogenous bone**		**The Graft + autogenous bone**		Pearson Chi-pătrat
	n	%	n	%	n	%	
	62	100.0%	30	100.0%	32	100.0%	
Gender							
Males	28	45.2%	13	43.3%	15	46.9%	Chi2 = 0.078
Females	34	54.8%	17	56.7%	17	53.1%	p = 0.779
Age groups							
40-59 yrs.	31	50.0%	15	50.0%	16	50.0%	Chi2 = 0.000
60-79 yrs.	31	50.0%	15	50.0%	16	50.0%	p = 1.000
Location							
Anterior	23	37.1%	13	43.3%	10	31.3%	Chi2 = 0.969
Posterior	39	62.9%	17	56.7%	22	68.8%	p = 0.431

Tabel 1.2. Descriptive data on alveolar bone sites

	Total		**BioOss + autogenous bone**		**The Graft + autogenous bone**		Pearson Chi-pătrat
	n	%	n	%	n	%	
	91	100.0%	41	100.0%	50	100.0%	
Gender							
Males	43	47.3%	19	46.3%	24	48.0%	Chi2 = 0.025
Females	48	52.7%	22	53.7%	26	52.0%	p = 0.875
Age groups							
40-59 yrs.	44	48.4%	20	48.8%	24	48.0%	Chi2 = 0.005
60-79 yrs.	47	51.6%	21	51.2%	26	52.0%	p = 0.941
Location							
Anterior	29	31.9%	13	31.7%	16	32.0%	Chi2 = 0.001
Posterior	62	68.1%	28	68.3%	34	68.0%	p = 0.976

Stages of guided bone regeneration technique (GBR)

The same oral surgery specialist, performed the guided tissue regeneration procedures at the implant sites. The surgical protocol is described further. Prophylactic administration of systemic antibiotic therapy was carried out for all patients preoperatively and for 4 days postoperatively.

Stages of surgical protocol in GBR technique:

DOI : 10.6261/RJOR.2024.3.16.11

1. Local anesthesia – Ubistezin (Sanofi, Germany);
2. Flap at the site of the alveolar bone defect;
3. Covering the exposed area with a thin layer of autogenous bone, followed by the placement of xenograft (BioOss, Geistlich, Germany; The Graft, Purgos Biologics, Korea);
4. Covering the grafted bone area with a resorbable barrier collagen membrane (Bio-Oss Collagen (Geislich, Germany);
5. Suturing surgical site (non-resorbables sutures polypropylene 5.0 Hu-Friedy, USA);
6. Postoperative follow-up stage (7 days): antibiotics, analgesics, rinsing the oral cavity with 0,5% chlorhexidine;
7. Removing sutures 9-11 days post-surgery.

Description of Bone Parameter Measurement Techniques. Analysis of Results

CBCT analysis of the results was performed 6 months post-addition.

The criteria for the success of the guided bone regeneration technique were as follows:

-absence of fistula;
-absence of mucosal dehiscence of the graft material particles;
-absence of chronic inflammation.

The CBCT examination (Sirona Orthophos XG) was used to measure alveolar bone parameters (preoperatively and six months postoperatively): height, width, and osteodensity of the alveolar bone at the implant sites.

Height measurements were taken from reference points located on the mandibular baseline. Width measurements were taken from points located on the buccal wall to points located on the oral wall. The parameters used in the CBCT examination were standardized (voltage 85 kV, 6 mA, irradiation duration 14.4 seconds, irradiation dose 25-1025 μSv, 1 mm sections).

CBCT images were stored in DICOM format. CBCT analysis was performed using the R2gate software application (Megagen, Korea).

The measurement of alveolar bone parameters pre- and post-addition was done by processing them in the aforementioned software applications. The protocol for measuring alveolar bone parameters was as follows:

-establishing reference areas with bone addition;
-selecting regions of interest;
-setting the parameters for the CBCT sections (1 mm thickness, 1 mm interval);
-performing 2D densitometric measurements at the representative section (values obtained were automatically expressed in Hounsfield units - HU).

Statistical Analysis

The data obtained from the two investigated groups were analyzed using statistical tests that compared bone gain (height, width, osteodensity) both intra-group (pre- vs. post-addition) and inter-group. Frequency distributions were calculated for qualitative variables, while means and standard deviations were calculated for quantitative variables. The normality of the data distribution was checked using the Shapiro-Wilks test. Comparison of quantitative variables between the test group and the control group was performed using the t-test and the Mann-Whitney test. Comparison of qualitative variables between the test group and the control group was performed using the Chi-square test. The significance level was set at $p < 0.05$. Statistical analysis was performed using SPSS version 27.0 for Windows.

Results

The following figures exemplify clinical and CBCT images (original, digitally processed) taken from the two patient groups (Group A - augmentation through guided tissue regeneration with

DOI : 10.6261/RJOR.2024.3.16.11

bovine-origin xenograft BioOss + autogenous bone; Group B - guided tissue regeneration technique with porcine-origin xenograft The Graft + autogenous bone).

The average values of the bone gains at the level of the reconstructed alveolar bone areas in terms of height, width, and osteodensity are exposed in tables 3.1.(height), 3.2 (width) and 3.3 (osteodensity) (overall groups; in relation to the assessed parameters).

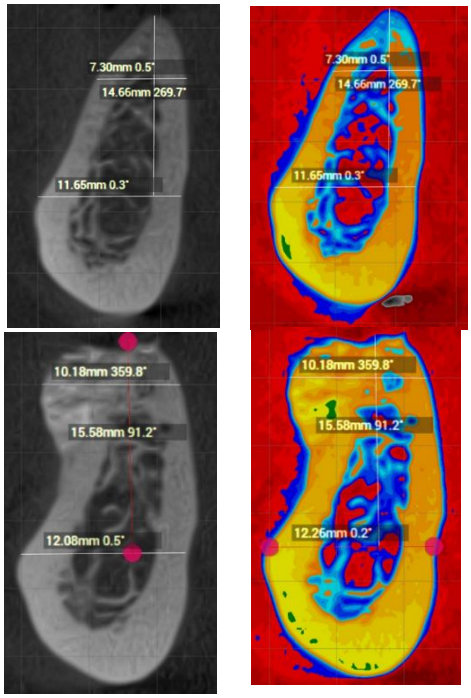

Fig.1.a-d. Original and digital eye filter (yellow- addition bone area; red– soft tissues; blue- D3 bone) applied on CBCT image: pre-operatory (fig.1.a-b) and 6 months post-operatory (fig.1.c-d)- change of alveolar bone parameters (height, width) in the reconstruction of alveolar bone area (3.6) with bovine-origin xenograft BioOss (Geistlich, Germany) and autogenous bone

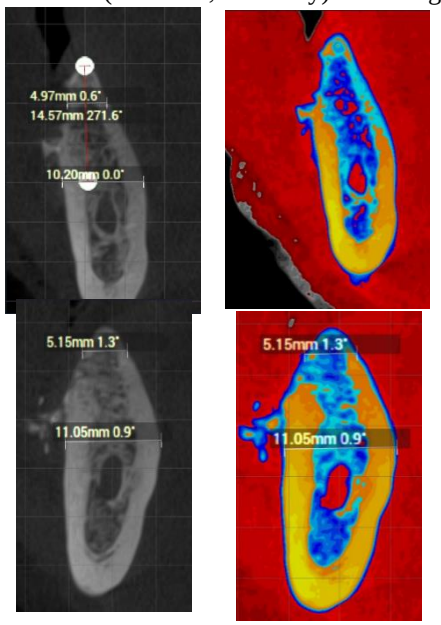

Fig.2.a-d. Fig.1.a-d. Original and digital eye filter (yellow- addition bone area; red– soft tissues; blue- D3 bone) applied on CBCT image: pre-operatory (fig.1.a-b) and 6 months post-operatory (fig.1.c-d)-

DOI : 10.6261/RJOR.2024.3.16.11

change of alveolar bone parameters (height, width) in the reconstruction of alveolar bone area (4.5) with porcine-origin xenograft The Graft (Purgos Biologics, Korea) and autogenous bone

Bone Gain (Height). For alveolar bone areas reconstructed with bovine-origin xenograft BioOss + autogenous bone, the average bone gain (height) values were 5.3076 mm. Bone gain was higher for male patients (5.1084 mm) compared to female patients (5.4795 mm), for the age group 40-59 years (5.7045 mm) compared to the age group 60-79 years (4.9295 mm), and for posterior implant sites (5.6439 mm) compared to anterior implant sites (4.5831 mm) (Table 3.1). For alveolar bone areas reconstructed with porcine-origin xenograft The Graft + autogenous bone, the average bone gain (height) values were 5.8736 mm. Bone gain was higher for female patients (6.4885 mm) compared to male patients (5.2075 mm), for the age group 60-79 years (6.5185 mm) compared to the age group 40-59 years (5.175 mm), and for posterior implant sites (6.0971 mm) compared to anterior implant sites (5.3988 mm) (Table 3.1).

Bone Gain (Horizontal). For alveolar bone areas reconstructed with bovine-origin xenograft BioOss + autogenous bone, the average bone gain (width) values were 4.4273 mm. Bone gain was higher for male patients (4.5805 mm) compared to female patients (4.2905 mm), for the age group 40-59 years (4.4965 mm) compared to the age group 60-79 years (4.3614 mm), and for posterior implant sites (4.5304 mm) compared to anterior implant sites (4.2054 mm) (Table 3.2). For alveolar bone areas reconstructed with porcine-origin xenograft The Graft + autogenous bone, the average bone gain (width) values were 4.1264 mm. Bone gain was higher for female patients (4.3131 mm) compared to male patients (3.999 mm), for the age group 60-79 years (4.4554 mm) compared to the age group 40-59 years (3.845 mm), and for posterior implant sites (4.3565 mm) compared to anterior implant sites (3.750 mm) (Table 3.2).

Bone Gain (Osteodensity). For alveolar bone areas reconstructed with bovine-origin xenograft BioOss + autogenous bone, the average bone gain (osteodensity) values were 279.59 HU. Bone gain was higher for female patients (320.5 HU) compared to male patients (323.21 HU), for the age group 40-59 years (301.4 HU) compared to the age group 60-79 years (258.8 HU), and for anterior implant sites (341.3 HU) compared to posterior implant sites (250.9 HU) (Table 3.3). For alveolar bone areas reconstructed with porcine-origin xenograft The Graft + autogenous bone, the average bone gain (osteodensity) values were 254.24 HU. Bone gain was higher for female patients (268.5 HU) compared to male patients (241.08 HU), for the age group 40-59 years (279.9 HU) compared to the age group 60-79 years (230.5 HU), and for posterior implant sites (270.7 HU) compared to anterior implant sites (219.2 HU) (Table 3.3).

Table 3.1. Gain bone (height) related to the assessed parameters

HEIGHT– Bone gain

		N	Mean	Std.error	Std.dev.	Median	Min	Max
Group A = BioOss + autogenous bone								
Gender	F	22	5.4795	.19929	.93477	5.5050	3.94	6.59
	M	19	5.1084	.33631	1.46594	4.7800	3.25	7.15
Age group	40-59 yrs.	20	5.7045	.27853	1.24563	6.1900	3.55	7.15
	60-79 yrs.	21	4.9295	.23301	1.06777	4.8400	3.25	6.93
Location	anterior	13	4.5831	.28711	1.03518	4.8000	3.25	6.08
	posterior	28	5.6439	.21696	1.14802	6.0000	3.55	7.15

DOI : 10.6261/RJOR.2024.3.16.11

Total		**41**	**5.3076**	**.18876**	**1.20867**	**4.9800**	**3.25**	**7.15**
Group B = The Graft + autogenous bone								
Gender	F	26	6.4885	.31008	1.58109	6.1100	4.00	10.64
	M	24	5.2075	.34604	1.69524	4.9500	3.57	10.13
Age group	40-59 yrs.	24	5.1750	.35098	1.71943	4.9500	3.57	10.13
	60-79 yrs.	26	6.5185	.30013	1.53035	6.1100	4.45	10.64
Locatioon	anterior	16	5.3988	.19340	.77359	5.5000	3.86	6.23
	posterior	34	6.0971	.34660	2.02103	5.8300	3.57	10.64
	Total	**50**	**5.8736**	**.24667**	**1.74422**	**5.7700**	**3.57**	**10.64**

Table 3.2. Gain bone (width) related to the assessed parameters

WIDTH– Bone gain

		N	Mean	Std.error	Std.dev.	Median	Min	Max
Group A = BioOss + autogenous bone								
Gender	F	22	4.2950	.29561	1.38655	4.1700	2.16	6.11
	M	19	4.5805	.23511	1.02484	4.9000	3.00	5.87
Age group	40-59 yrs.	20	4.4965	.28928	1.29368	4.3550	2.19	6.11
	60-79 yrs.	21	4.3614	.25877	1.18584	4.3300	2.16	5.98
Location	anterior	13	4.2054	.39909	1.43894	4.3300	2.16	5.98
	posterior	28	4.5304	.21308	1.12753	4.3550	2.66	6.11
Total		**41**	**4.4273**	**.19145**	**1.22586**	**4.3400**	**2.16**	**6.11**
Group B = The Graft + autogenous bone								
Gender	F	26	4.3131	.36365	1.85428	4.2200	1.90	8.53
	M	24	3.9992	.20588	1.00858	4.1400	2.21	6.10
Age group	40-59 yrs.	24	3.8450	.20691	1.01367	3.8300	2.21	6.10
	60-79 yrs.	26	4.4554	.35584	1.81442	4.2800	1.90	8.53
Location	Anterior	16	3.7500	.29999	1.19994	4.1650	1.90	5.32
	posterior	34	4.3565	.27522	1.60478	4.2200	2.86	8.53
	Total	**50**	**4.1624**	**.21245**	**1.50228**	**4.2200**	**1.90**	**8.53**

Table 5.6.3. Gain bone (osteodensity) related to the assessed parameters

OSTEODENSITY– Bone gain

		N	Media	Eroarea std. a mediei	Deviația std.	Mediana	Min	Max
Group A = BioOss + autogenous bone								
Gender	F	22	320.50	41.592	195.083	297.50	65	851
	M	19	232.21	29.493	128.557	215.00	71	448
Age group	40-59 yrs.	20	301.40	48.488	216.845	308.00	65	851
	60-79 yrs.	21	258.81	25.079	114.927	262.00	71	448
Location	anterior	13	341.31	22.093	79.659	336.00	241	448
	posterior	28	250.93	36.866	195.078	212.00	65	851
Total		**41**	**279.59**	**26.780**	**171.476**	**265.00**	**65**	**851**
Group B = The Graft + autogenous bone								
Gender	F	26	241.08	24.800	126.458	232.00	10	430
	M	24	268.50	21.324	104.465	300.00	77	436
Age group	40-59 ani	24	279.92	22.997	112.661	300.00	77	436
	60-79 ani	26	230.54	22.797	116.244	225.00	10	430
Location	anterior	16	219.25	26.008	104.030	215.00	10	335
	posterior	34	270.71	20.446	119.219	291.00	77	436
	Total	**50**	**254.24**	**16.415**	**116.073**	**247.00**	**10**	**436**

Discussions

The techniques of guided bone regeneration using xenografts have been

DOI : 10.6261/RJOR.2024.3.16.11

investigated by numerous research groups, but few studies have examined the bone gain achieved by combining graft biomaterials with biologically impactful materials such as autogenous bone. Given that a large proportion of implant sites require augmentation of the alveolar bone volume to achieve optimal implant stability and long-term prosthetic success, evaluating the bone gain achieved through bone addition techniques that utilize xenografts and autogenous bone represents a highly relevant research area.

Xenografts have distinct physicochemical and structural properties for which they are recommended in the reconstruction of the alveolar bone, with or without the association of autogenous bone. Porcine-origin xenografts have a crystalline structure similar to human bone tissue [11]. In group B, the alveolar bone was rehabilitated usin porcine-origin xenograft (The Graft) with a high degree of porosity (78.4%) and an extensive specific surface area (SSA; 69.9 m^2/g), a high surface roughness (4.47 μm), and a high percentage of pores with a diameter <100 nm (78.4%). These values are higher than those of the bovine-origin xenograft Bio-Oss®. At the same time, the porosity values are similar to those of human trabecular bone porosity (79.3%). This is an important property because the macropores and micropores that characterize the structure of a xenograft significantly influence the biomaterial's ability to stimulate new bone tissue formation [12]. The presence of micropores in the structure of these biomaterials is very important because osteoblasts adhering to xenograft surfaces with nanoparticles smaller than 100 nm in diameter exhibit superior proliferation rates, higher alkaline phosphatase synthesis rates, and mineral deposition on the extracellular matrix [13]. Additionally, the high degree of hydrophilicity and increased surface energy of the porcine-origin xenograft The Graft allows for higher protein absorption rates, increased cell adhesion rates, and stimulation of cell proliferation processes [14, 15].

As demonstrated by the results obtained in my study, the use of xenografts combined with autogenous bone in the reconstruction of alveolar bone through guided bone regeneration (GBR) is an effective technique. The results can be explained by both the regenerative properties of autogenous bone and the osteoconductivity and biocompatibility of xenografts [16, 17]. When using the bovine-origin xenograft BioOss, the vertical bone gain was 5.3076 mm, the horizontal gain was 4.4273 mm, and the osteodensity of the grafted bone areas increased by 279.59 HU. With the porcine-origin xenograft TheGraft, the vertical bone gain was 5.8736 mm, the horizontal gain was 4.1624 mm, and the osteodensity of the grafted bone areas increased by 254.24 HU. Regarding the statistical comparisons between the two groups for patient gender (male vs. female), age groups (40-59 years vs. 60-79 years), and implant site location, intra-group statistical analysis detected statistically significant differences for all investigated parameters. Factors that can influence osteodensity changes include the type of biomaterial, the volume of the graft material, the compaction technique, the degree of sealing, the use or non-use of membranes, the type of membranes used, and the use or non-use of the PRF technique [18].

The results of personal study regarding vertical and horizontal bone gain confirm data from literature provided by studies focused on guided bone regeneration techniques using xenografts and autogenous bone. Regarding the effectiveness of augmentation techniques using xenografts as the sole graft material, Troeltzsch et al. (2016) investigated the rate of new bone tissue formation, the success rate in bone defect rehabilitation, the degree of horizontal and vertical bone gain, the post-operative increase in osteodensity in the grafted areas, the post-operative

DOI : 10.6261/RJOR.2024.3.16.11

resorption rate, and the post-operative complication rate [19]. They concluded that, regardless of the technique used, xenograft materials lead to an average horizontal bone gain of 4.5 mm. A research group conducting a similar study investigated the effectiveness of guided bone regeneration using mixed grafts of autogenous bone and xenograft combined with resorbable collagen membranes. They reported increased average osteodensity values (D2 and D3 type bone tissue) and an average horizontal bone gain of 4.65 mm at 6 months post-operation [20]. Another research group that investigated guided bone regeneration techniques using a combination of xenograft and autogenous bone reported average alveolar bone height values of 5.5 ± 0.30 mm, immediate post-addition values of 14.51 ± 0.27 mm, and 6-month post-addition values of 13.77 ± 0.32 mm, with an average bone resorption of 0.74 ± 0.05 mm at 6 months post-operation [21]. A research group evaluated the vertical bone gain obtained with the bovine-origin xenograft material Bio-Oss in alveolar bone reconstruction techniques performed in the pre-implantation stage. The results obtained after statistical processing of the data provided by CBCT evaluation immediately post-operation and at 6 months post-operation were as follows: the vertical bone gain was 6.56 ± 3.54 mm for the Bio-Oss® group, and histomorphometric analysis regarding the rate of new bone tissue formation showed that in alveolar sites augmented with Bio-Oss®, the percentage of new bone tissue was 35.00 ± 19.33% [22]. Monje et al. (2015) used CBCT examination to evaluate horizontal bone augmentation using autogenous bone blocks combined with xenograft in guided bone regeneration techniques for reconstructing severely defective maxillary alveolar bone (class III-IV cases according to Cadwood and Howell classification). The study was conducted on 19 alveolar sites, rehabilitated within a study group of 14 patients. Horizontal bone gain was recorded by CBCT at 3 levels (5, 7, and 11 mm from the residual ridge) at the time of bone grafting and 5 months post-operation (prior to implantation). The average horizontal bone gain varied between 3.23-4.93 mm compared to the donor area of the autogenous bone. The authors concluded that a combination of autogenous bone blocks with xenograft and resorbable collagen membrane is a predictable technique for horizontal augmentation of anterior maxillary alveolar sites [23]. Sánchez-Labrador et al. (2021) reviewed the literature to evaluate the effectiveness of guided bone regeneration techniques using autogenous bone blocks combined with xenografts compared to reconstruction with autogenous bone as the sole graft material by analyzing block survival rates, block resorption, subsequent implant survival rates, post-surgical complications, and histomorphometric studies. The studies included investigated a total of 333 patients, with 337 sites reconstructed with xenogenic bone blocks and 82 sites reconstructed with autogenous bone blocks. Failure rates were 6.82% (xenograft and autogenous bone combinations) and 6.1% (autogenous bone). Bone gain, both in height and width, was similar between the two categories of materials used, but the resorption rate of autogenous bone blocks was significantly higher. Following the review of studies based on histological and histomorphometric analyses, the authors reported larger areas of new bone tissue and smaller areas of residual bone substitute in sites reconstructed with autogenous bone blocks compared to alveolar sites reconstructed with xenograft and autogenous bone combinations. The review authors recommend reconstructing atrophic alveolar ridges with xenogenic bone block grafts (xenografts + autogenous bone) as a viable alternative to autogenous bone block grafts, with benefits including reduced autogenous bone harvest volume, similar

DOI : 10.6261/RJOR.2024.3.16.11

failure rates, and lower rates of post-operative complications [24].

The results obtained in my study demonstrate the importance of adapting the surgical protocol to the individual factors and conditions of the patients and the role of CBCT in diagnosing and treating bone defects to allow for optimal positioning of dental implants [25]. Regarding the study's limitations, these may include the small number of patients and the absence of preoperative data on alveolar bone classification or the extent of bone defects.

Conclusions

- The study results demonstrate the effectiveness of guided bone regeneration techniques in reconstructing deficient alveolar areas by combining xenografts with autogenous bone.
- Post-operative bone gain in vertical and horizontal dimensions, as well as osteodensity, was statistically significant both in the overall group and for each of the investigated categories (sex, age group, location).
- The average vertical bone gain (height) was lower in alveolar sites reconstructed with bovine-origin xenografts combined with autogenous bone (5.3076 mm) compared to those reconstructed with porcine-origin xenografts combined with autogenous bone (5.8736 mm).
- The average horizontal bone gain (width) was higher in alveolar sites reconstructed with bovine-origin xenografts combined with autogenous bone (4.4273 mm) compared to those reconstructed with porcine-origin xenografts combined with autogenous bone (4.1624 mm).
- The average osteodensity gain was higher in alveolar sites reconstructed with bovine-origin xenografts combined with autogenous bone (279.59 HU) compared to those reconstructed with porcine-origin xenografts combined with autogenous bone (254.24 HU).

References

1. Sakkas A, Wilde F, Heufelder M, Winter K, Schramm A. Autogenous bone grafts in oral implantology-is it still a "gold standard"? A consecutive review of 279 patients with 456 clinical procedures. *Int J Implant Dent.* 2017 Dec;3(1):23. doi: 10.1186/s40729-017-0084-4.
2. Yang Z, Liang Q, Lu H, Chu H, Gan Z, Rong M. Clinical Outcomes of Alveolar Ridge Augmentation with In Situ Autogenous Block Bone: A Retrospective Review. *Int J Oral Maxillofac Implants.* 2021 Sep-Oct;36(5):1008-1015.
3. de Freitas RM, Susin C, Spin-Neto R, Marcantonio C, Wikesjö UM, Pereira LA, Marcantonio E Jr. Horizontal ridge augmentation of the atrophic anterior maxilla using rhBMP-2/ACS or autogenous bone grafts: a proof-of-concept randomized clinical trial. *J Clin Periodontol.* 2013 Oct;40(10):968-75.
4. Elsayed AO, Abdel-Rahman FH, Ahmed WMAS, *et al*. Clinical and Radiographic Outcomes of Autogenous Inlay Graft vs Autogenous Onlay Graft for Anterior Maxillary Horizontal Ridge Augmentation: A Randomized Control Clinical Study. *J Contemp Dent Pract* 2024;25(2):107-113.
5. Atef M, Osman AH, Hakam M. Autogenous interpositional block graft vs onlay graft for horizontal ridge augmentation in the mandible. *Clin Implant Dent Relat Res.* 2019 Aug;21(4):678-685.
6. Di Stefano DA, Orlando F, Ottobelli M, Fiori D, Garagiola U. A comparison between anorganic bone and collagen-preserving bone xenografts for alveolar ridge preservation: systematic review and future perspectives. *Maxillofac Plast Reconstr Surg*. 2022 Jul 12;44(1):24. doi: 10.1186/s40902-022-00349-3
7. Christensen JG, Grønlund GP, Georgi SR, Starch-Jensen T, Bruun NH, Jensen SS. Horizontal Alveolar Ridge Augmentation with Xenogenic Block Grafts Compared with Autogenous Bone

DOI : 10.6261/RJOR.2024.3.16.11

Block Grafts for Implant-retained Rehabilitation: a Systematic Review and Meta-Analysis. *J Oral Maxillofac Res.* 2023 Jun 30;14(2):e1. doi: 10.5037/jomr.2023.14201.
8. Starch-Jensen T, Deluiz D, Tinoco EMB. Horizontal Alveolar Ridge Augmentation with Allogeneic Bone Block Graft Compared with Autogenous Bone Block Graft: a Systematic Review. *J Oral Maxillofac Res.* 2020 Mar 31;11(1):e1. doi: 10.5037/jomr.2020.11101.
9. Gorgis R, Qazo L, Bruun NH, Starch-Jensen T. Lateral Alveolar Ridge Augmentation with an Autogenous Bone Block Graft Alone with or without Barrier Membrane Coverage: a Systematic Review and Meta-Analysis. *J Oral Maxillofac Res.* 2021 Sep 30;12(3):e1.
10. Zaki J, Alnawawy M, Yussif N, Elkhadem A. The Effect of Membrane Coverage on the Resorption of Autogenous Intraoral Block Grafts in Horizontal Ridge Augmentation: A Systematic Review of Literature and Meta-Analysis: Inevitability or an Iatrogenic Vulnerability? *J Evid Based Dent Pract*. 2018 Dec;18(4):275-289.
11. Bracey DN, Seyler TM, Jinnah AH, Lively MO, Willey JS, Smith TL, Van Dyke ME, Whitlock PW. A Decellularized Porcine Xenograft-Derived Bone Scaffold for Clinical Use as a Bone Graft Substitute: A Critical Evaluation of Processing and Structure.*J Funct Biomater*.2018, 12; 9(3): 45.
12. Lee DS, Pai Y, Chang S. Physicochemical characterization of InterOss® and Bio-Oss® anorganic bovine bone grafting material for oral surgery: a comparative study. *Mater Chem Phys.* 2014;146:99–104.
13. Webster TJ, Ergun C, Doremus RH, Siegel RW, Bizios R. Enhanced functions of osteoblasts on nanophase ceramics. *Biomaterials* 2000;21:1803–1810.
14. Kubies D, Himmlová L, Riedel T, Chánová E, Balík K, Douděrová M, et al. The interaction of osteoblasts with bone-implant materials: 1. The effect of physicochemical surface properties of implant materials. *Physiol Res* 2011;60:95–111.
15. Rupp F, Gittens RA, Scheideler L, Marmur A, Boyan BD, Schwartz Z, et al. A review on the wettability of dental implant surfaces I: theoretical and experimental aspects. *Acta Biomater* 2014;10:2894–2906.
16. Cavdar FH, Keceli HG, Hatipoglu H, Demiralp B, Caglayan F. Evaluation of Extraction Site Dimensions and Density Using Computed Tomography Treated With Different Graft Materials: A Preliminary Study. *Implant Dent*. 2017;26(2):270-274.
17. Kim DH, Kim KI, Yoon S, Kim HJ, Ahn JS, Jun SH, et al. Dental hetero-graft materials with nano hydroxyapatite surface treatment. *J Nanosci Nanotechnol* 2015;15:7942–7949.
18. Misch CM. Dental implant prosthetics. Missouri: Mosby, 2014, p.1008.
19. Troeltzsch M, Troeltzsch M, Kauffmann P, Gruber R, Brockmeyer P, Moser N, Rau A, Schliephake H. Clinical efficacy of grafting materials in alveolar ridge augmentation: A systematic review. *J Craniomaxillofac Surg*. 2016 Oct;44(10):1618-1629.
20. Proussaefs P, Lozada J. Use of titanium mesh for staged localized alveolar ridge augmentation: clinical and histologic-histomorphometric evaluation. *J Oral Implantol.* 2006;32(5):237–247. doi: 10.1563/1548-1336
21. Fala V. Tratamentul complex la pacienţii cu parodontită cronicã şi edentaţii. Chişinău, 2015.
22. Pang KM, Um IW, Kim YK, Woo JM, Kim SM, Lee JH. Autogenous demineralized dentin matrix from extracted tooth for the augmentation of alveolar bone defect: a prospective randomized clinical trial in comparison with anorganic bovine bone. *Clin Oral Implants Res*. 2017 Jul; 28(7):809-815.
23. Monje A, Monje F, Hernández-Alfaro F, Gonzalez-García R, Suárez-López del Amo F, Galindo-Moreno P, Montanero-Fernández J, Wang HL. Horizontal Bone Augmentation Using Autogenous Block Grafts and Particulate Xenograft in the Severe Atrophic Maxillary Anterior Ridges: A Cone-Beam Computerized Tomography Case Series. *J Oral Implantol*. 2015 Jul;41 Spec No:366-71. doi: 10.1563/AAID-JOI-D-13-00219.
24. Sánchez-Labrador L, Molinero-Mourelle P, Pérez-González F, Saez-Alcaide LM, Brinkmann JC, Martínez JL, Martínez-González JM. Clinical performance of alveolar ridge augmentation with xenogeneic bone block grafts versus autogenous bone block grafts. A systematic review. *J Stomatol Oral Maxillofac Surg.* 2021 Jun;122(3):293-302.
25. Tolstunov L. Surgical Algorithm for Alveolar Bone Augmentation in Implant Dentistry. *Oral Maxillofac Surg Clin North Am.* 2019;31(2):155–161.

DOI : 10.6261/RJOR.2024.3.16.11